

Clinical Case

NobelReplace Platform Shift

October, 2011




NobelReplace Platform Shift



Professor Alessandro Pozzi

Surgeon & Prosthodontist

Italy



Flap with augmentation

Female patient

70 years old

Implants:

NobelReplace PS NP

4.3x13mm

NobelReplace PS RP

5.0x13mm

NobelReplace PS RP

5.0x16mm

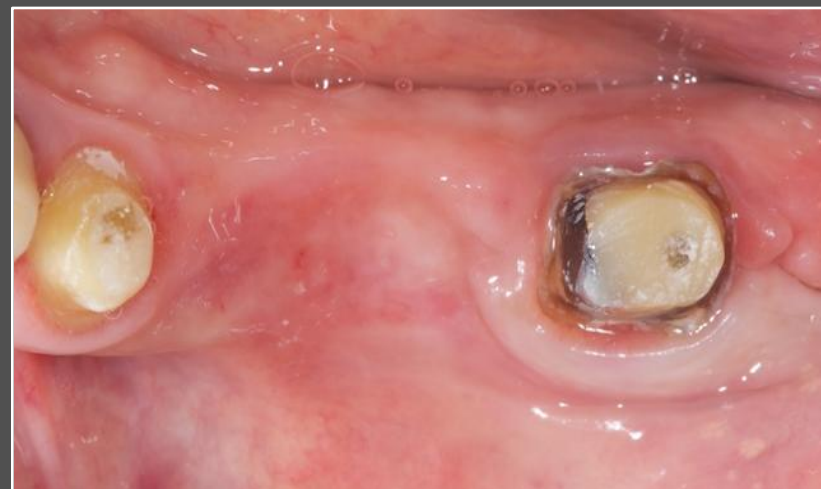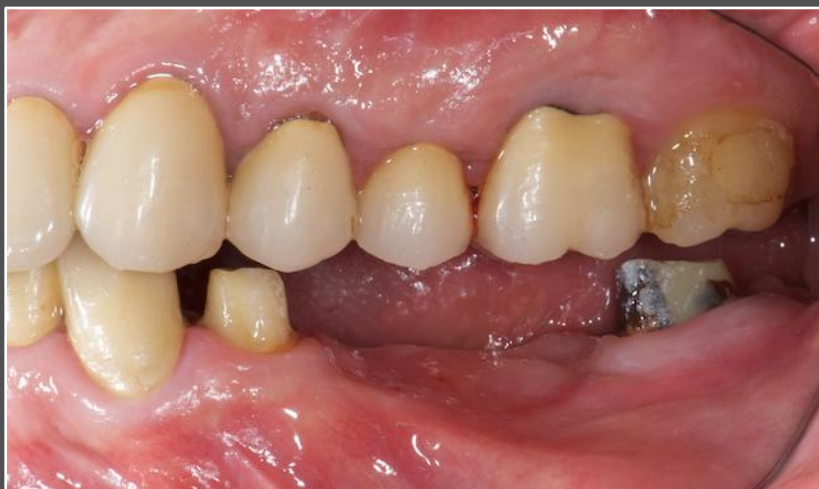Surgery date:

May 2nd, 2011

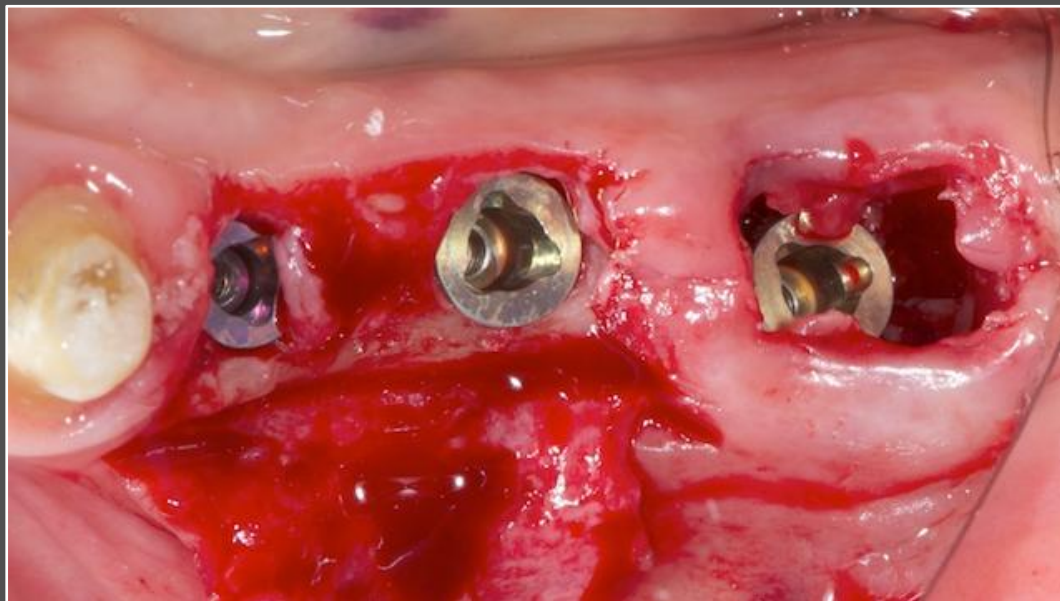FDI POS: teeth 35, 36, 37

NobelReplace Platform Shift

Initial clinical situation

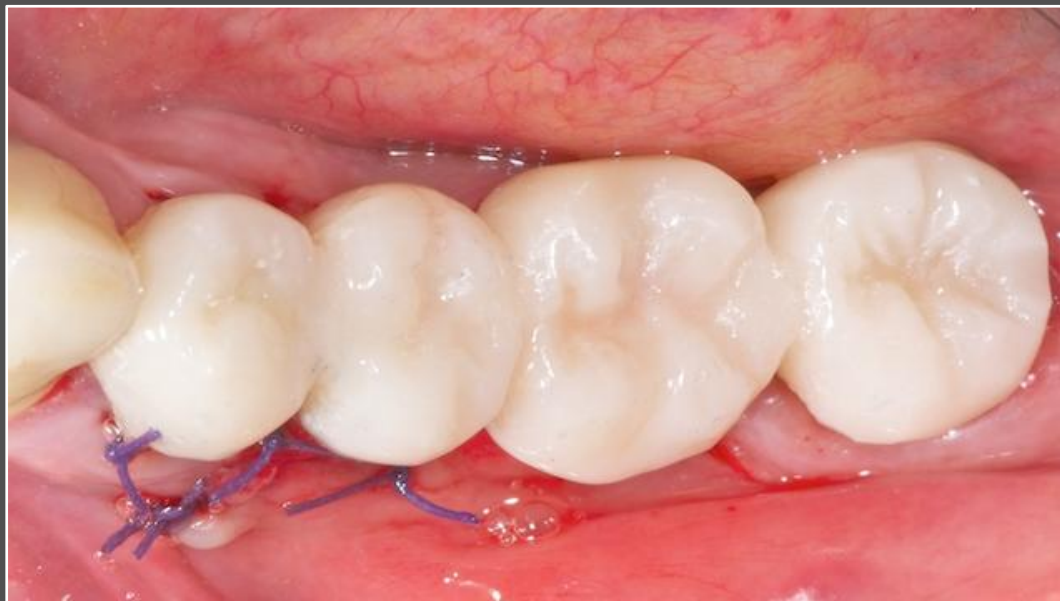

NobelReplace Platform Shift



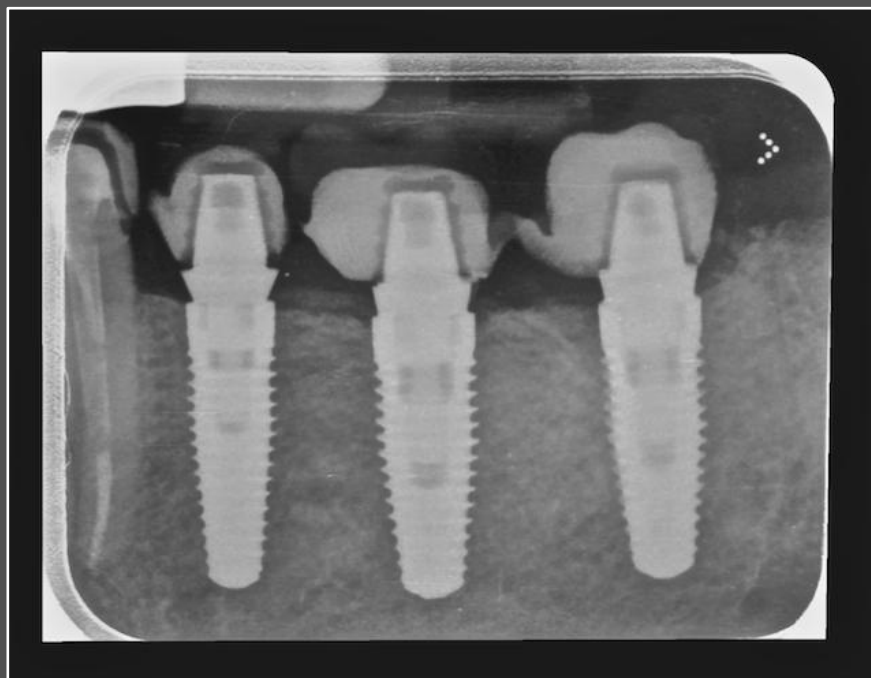
Extraction of #37 with a placement of NobelReplace PS at #35, 36 and 37.

NobelReplace Platform Shift



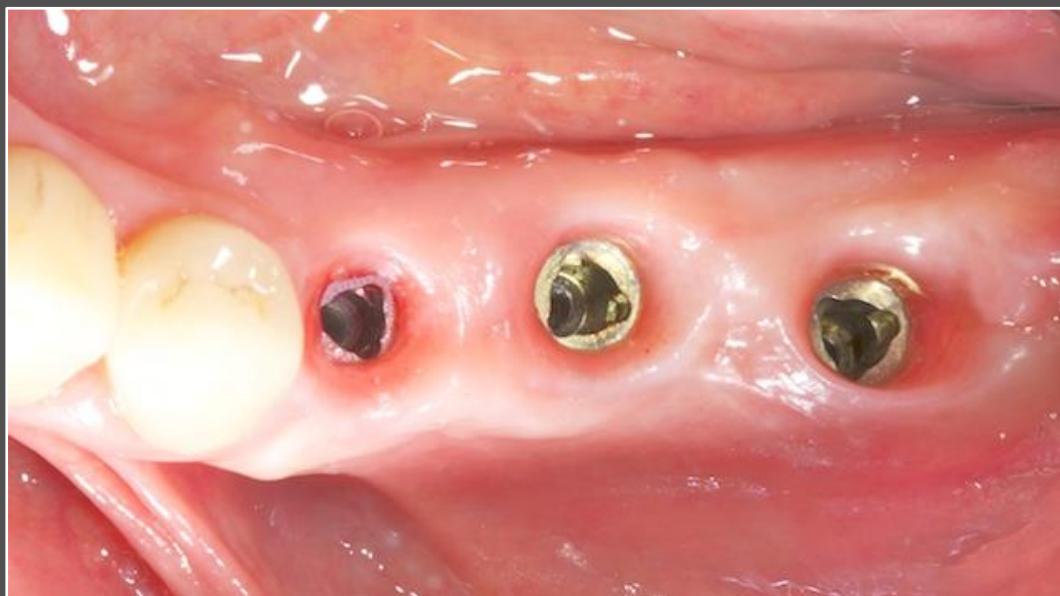Temporary restoration with quick temporary abutments on implants #35, 36 and 37, and on tooth #34.

NobelReplace Platform Shift



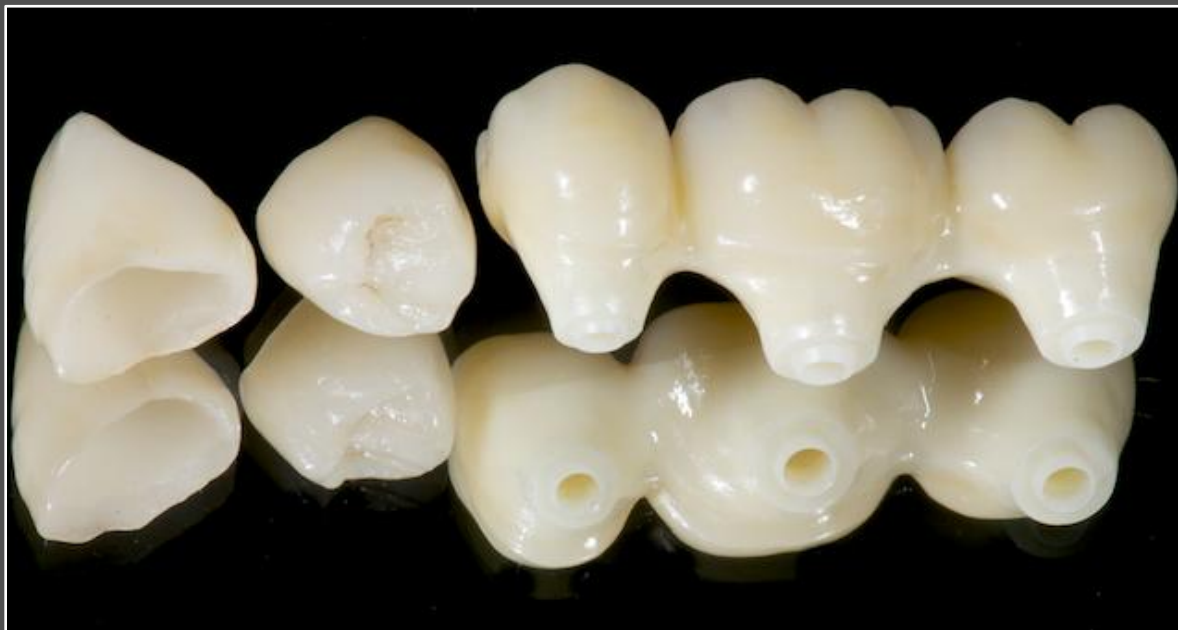Post-operative radiograph.

NobelReplace Platform Shift



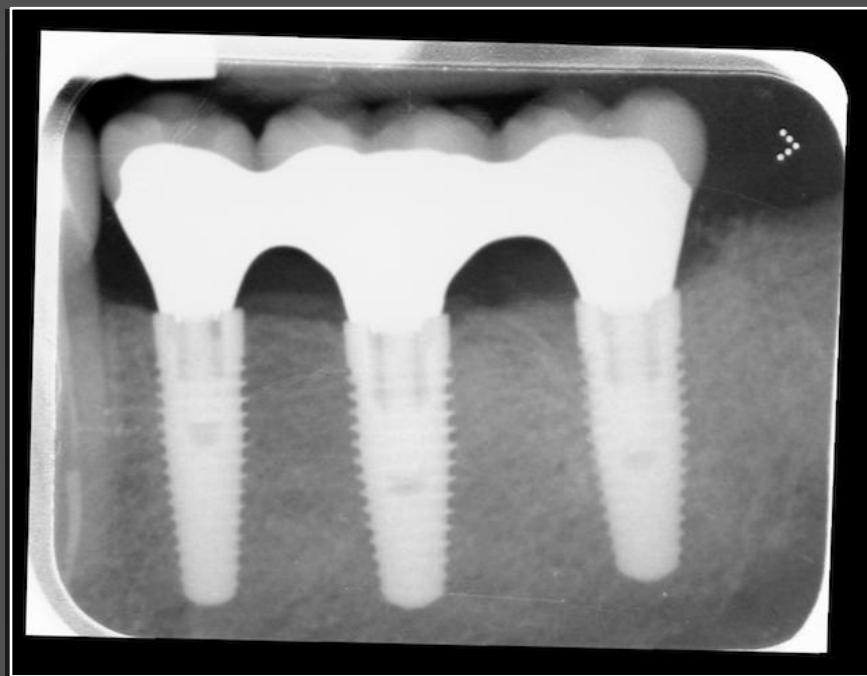Soft tissue appearance after 4 months healing period.

NobelReplace Platform Shift



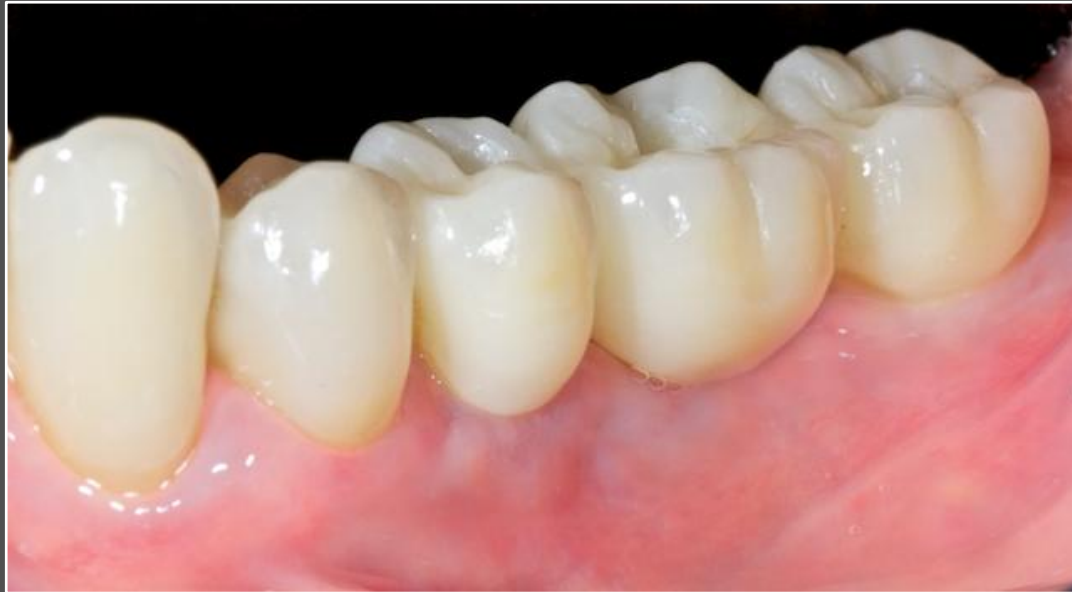Procera implant bridge on implant level with 2 Procera crowns on teeth.

NobelReplace Platform Shift



Final radiograph.

NobelReplace Platform Shift



Definitive restoration on NobelReplace PS implants.