

# Clinical Case

## NobelReplace Platform Shift

---

October, 2011




# NobelReplace Platform Shift



Dr. Egon Euwe

Periodontist

Italy



**Anterior restoration**

Female patient

48 years old

**Implant:**

NobelReplace PS NP

4.3x13mm

**Surgery date:**

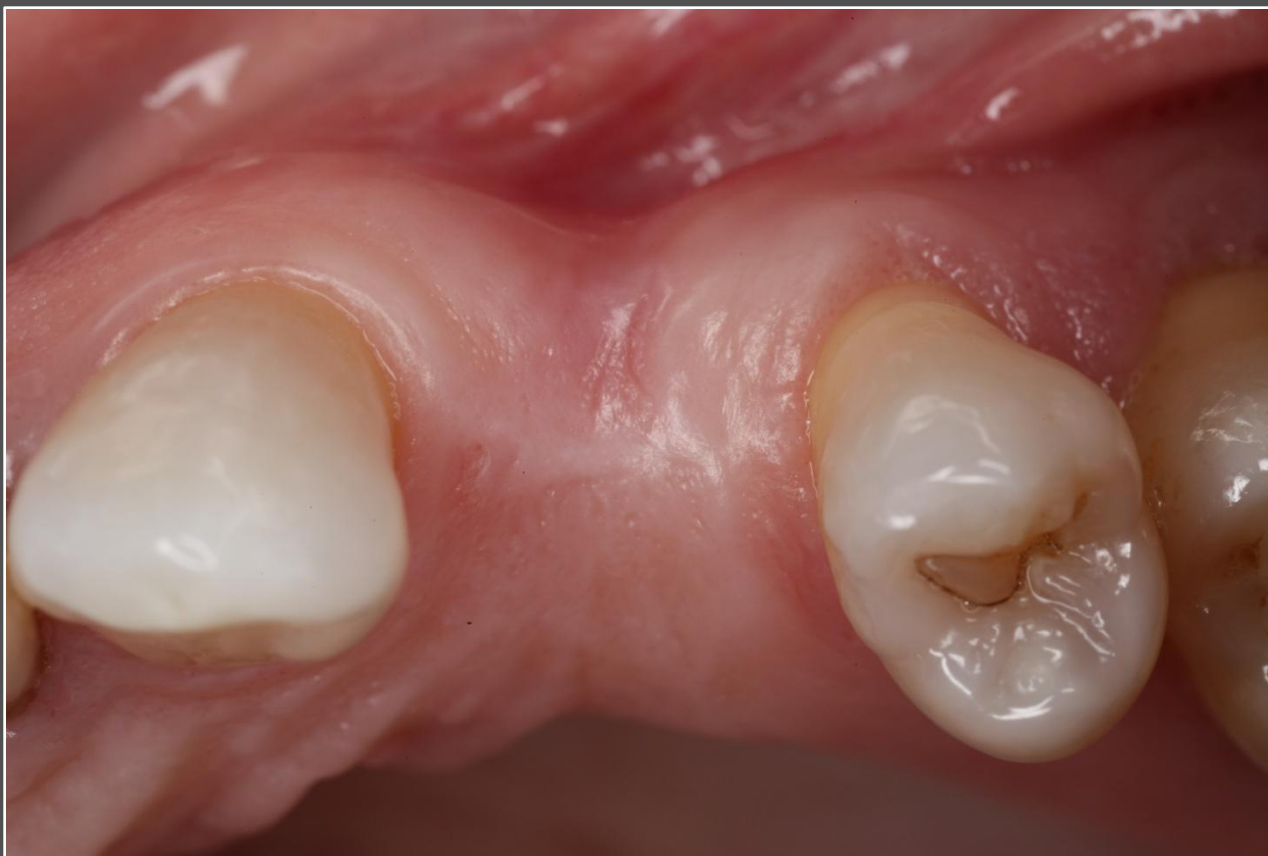February 25<sup>th</sup>, 2011

**Flap with augmentation**

**FDI POS:** tooth 24

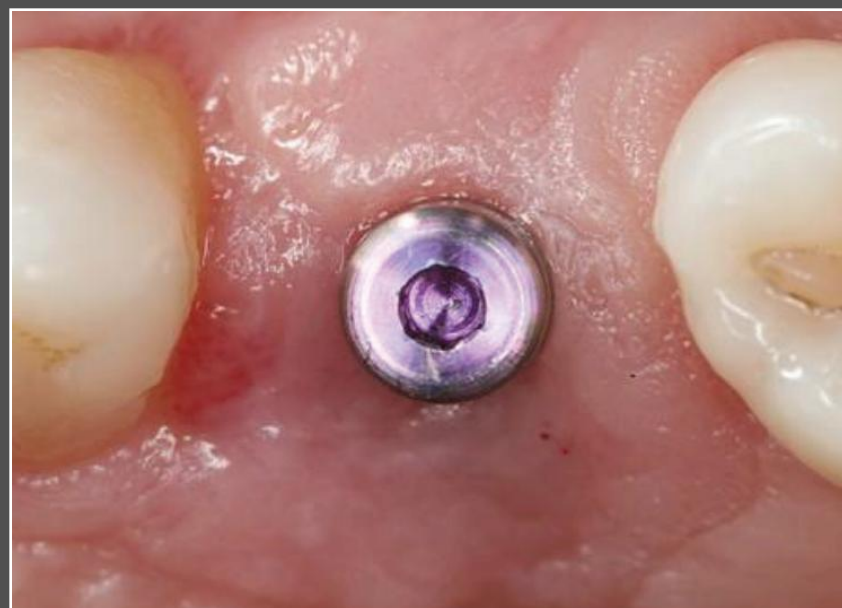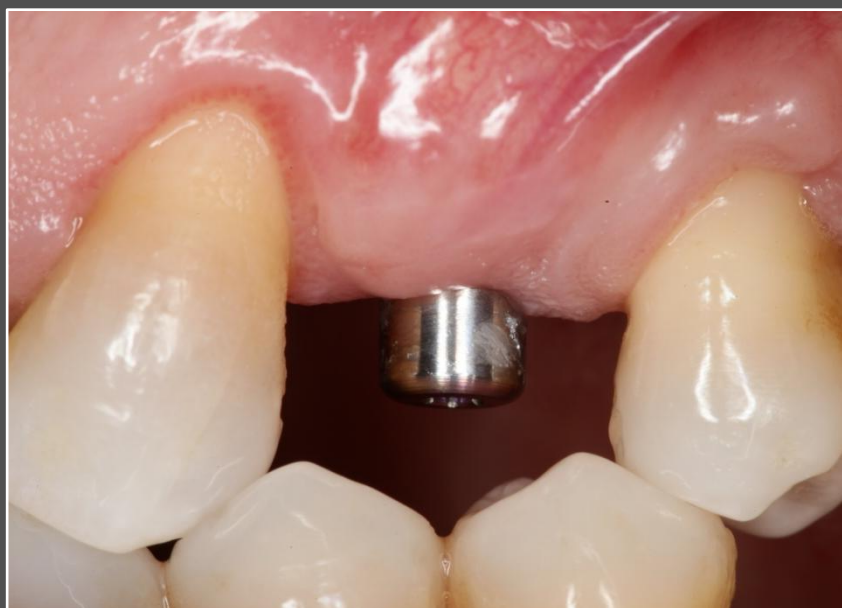# NobelReplace Platform Shift

Initial clinical situation

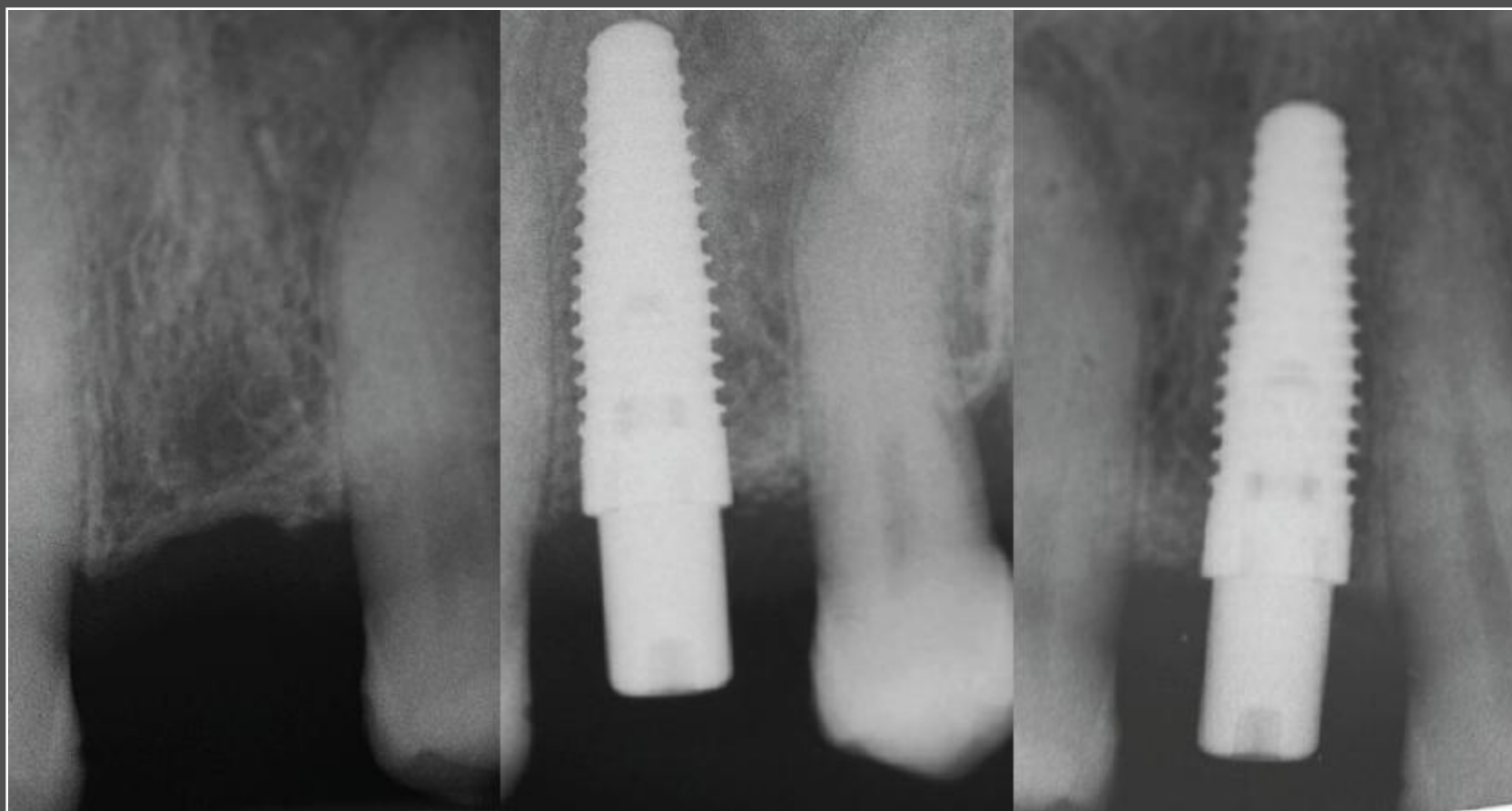


# NobelReplace Platform Shift

4 months post-op



# NobelReplace Platform Shift

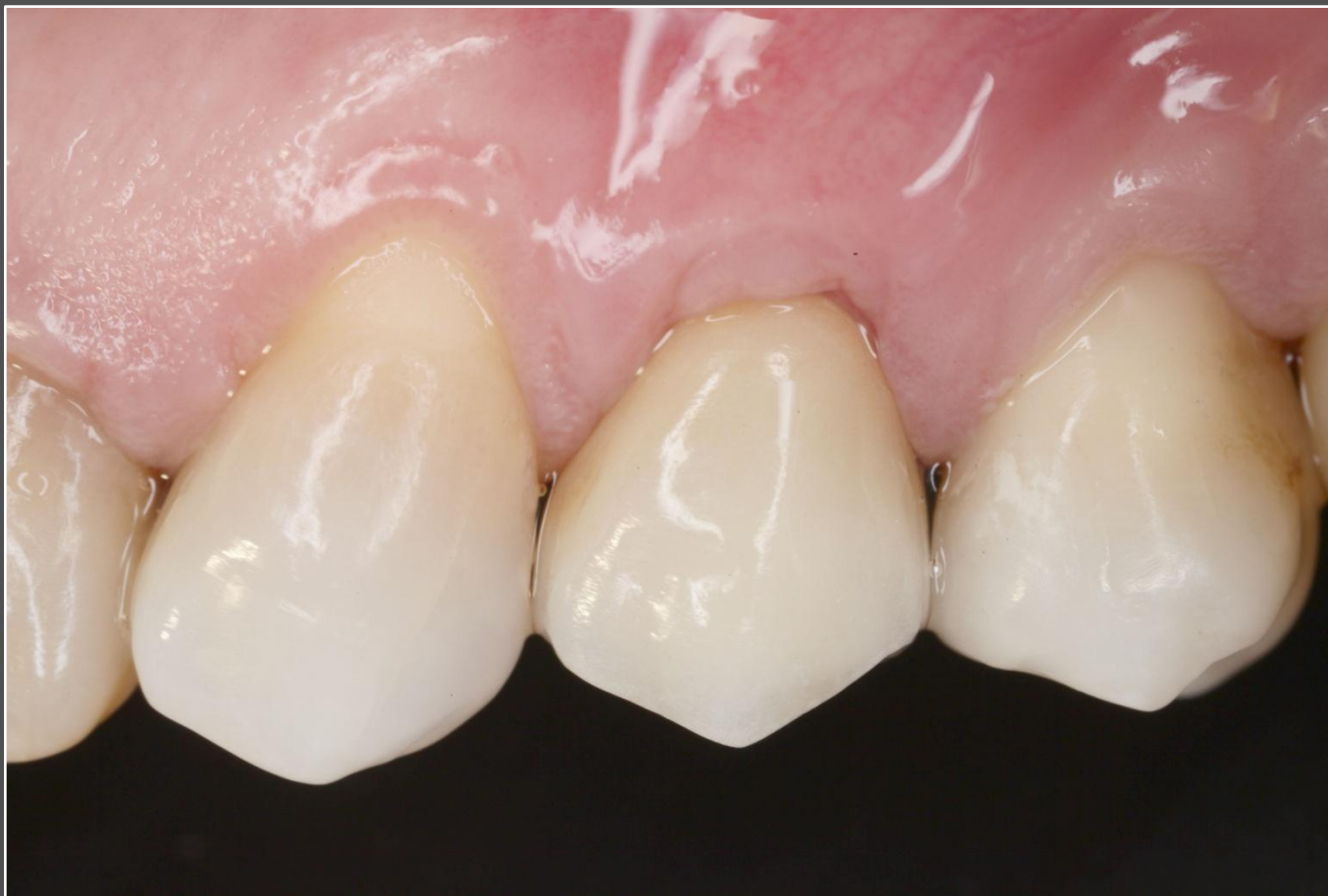

Pre-op radiograph

1 month post-op radiograph

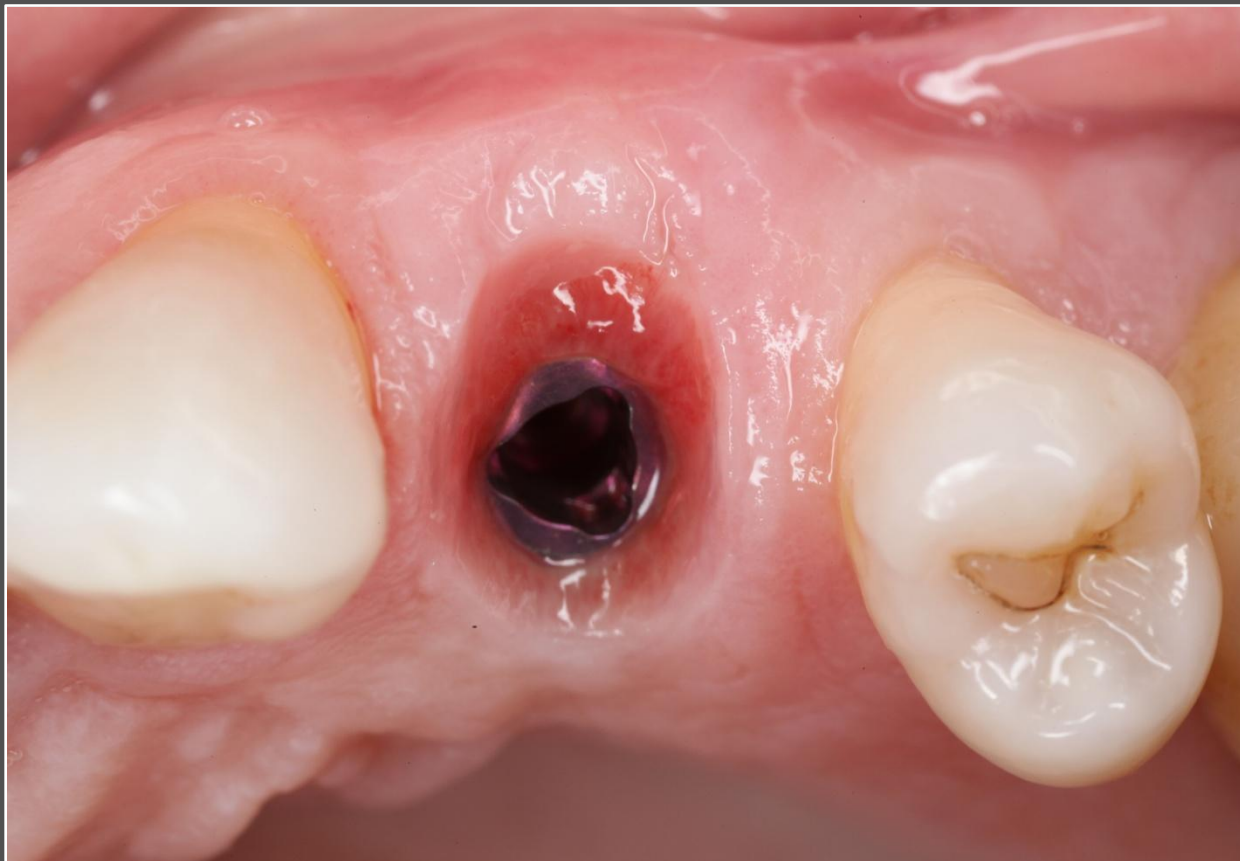
2 months post-op radiograph

# NobelReplace Platform Shift



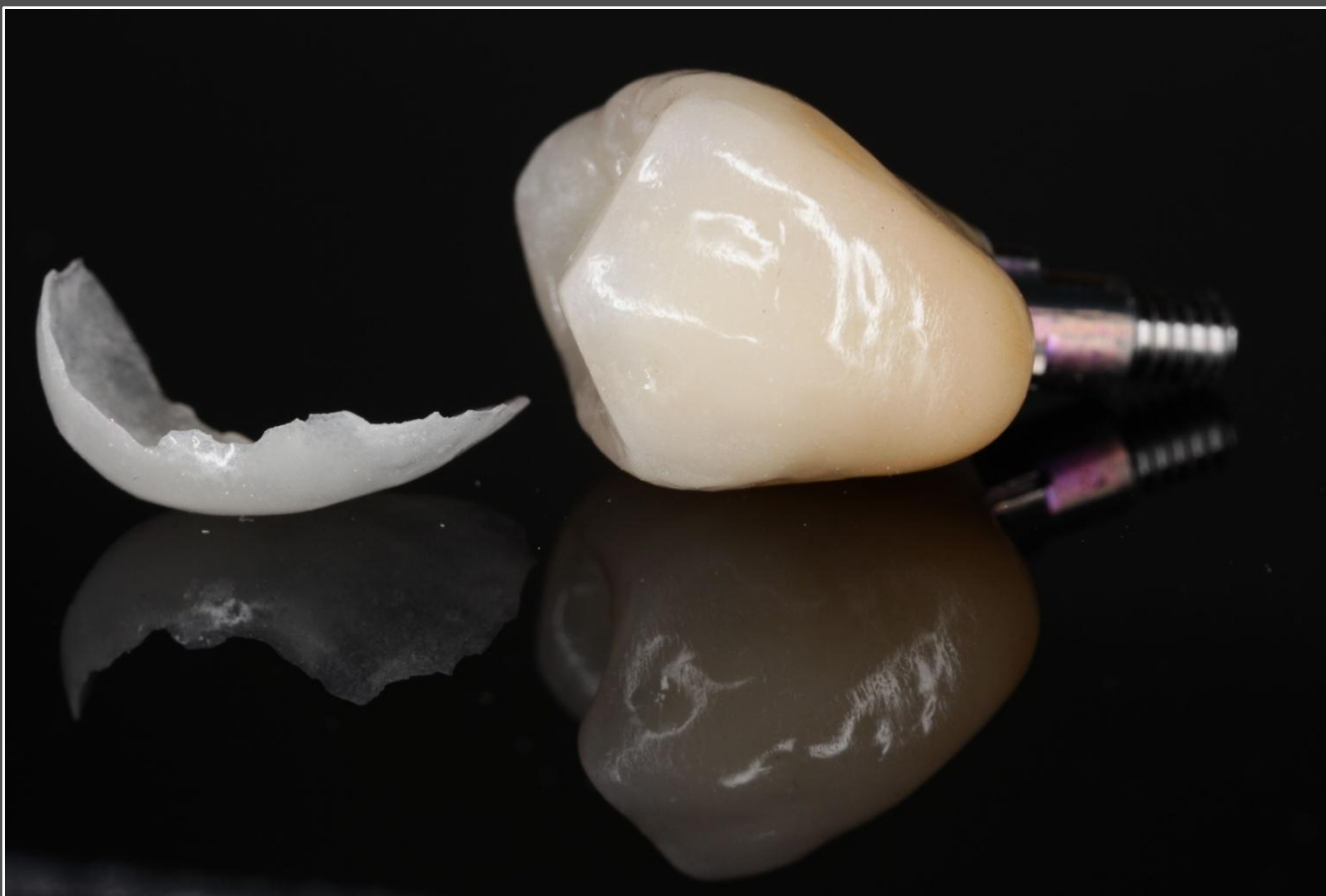4 months post-op, with temporary restoration

# NobelReplace Platform Shift



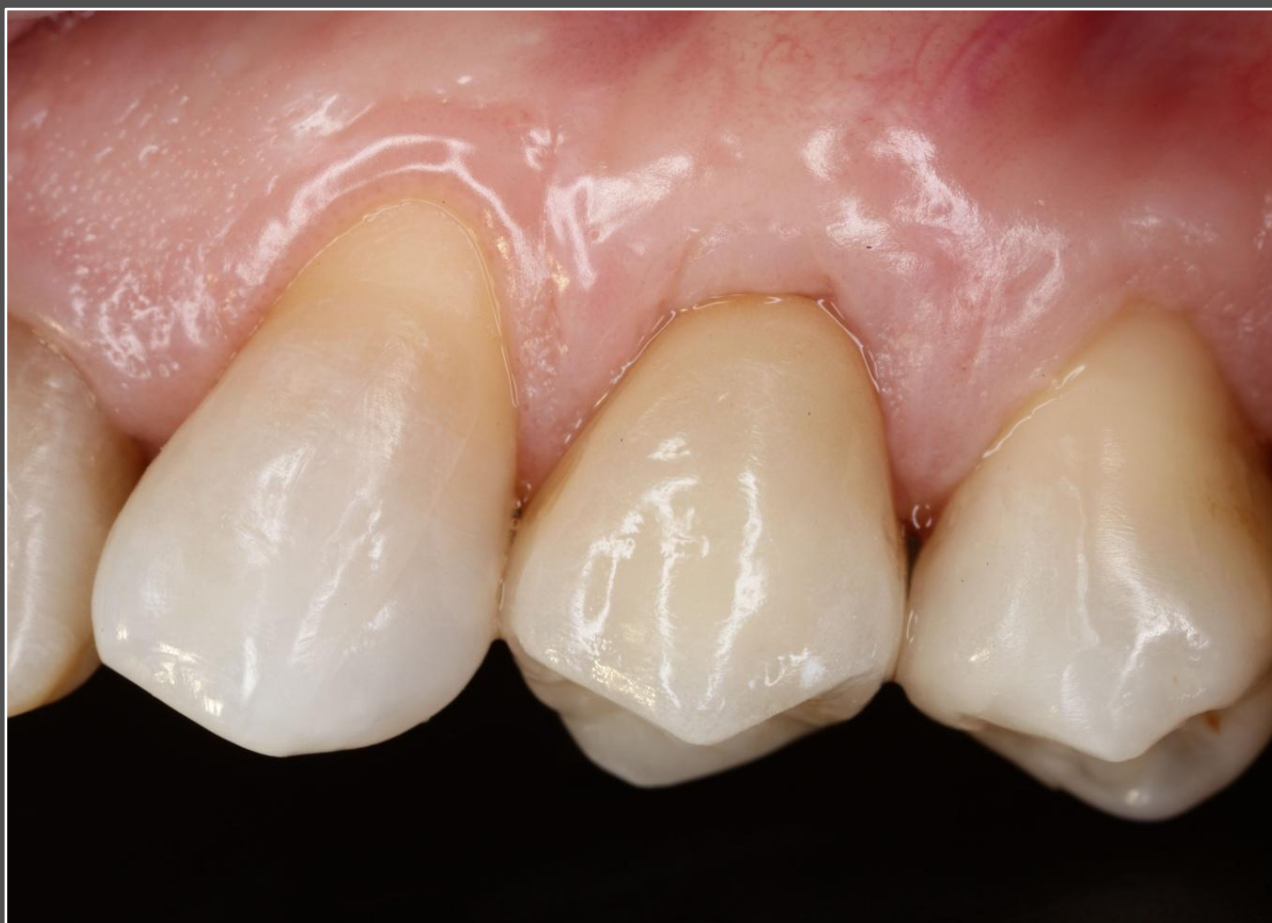Soft tissue volume achieved with platform shifting.

# NobelReplace Platform Shift



Veneer and crown fabricated on NobelProcera Zirconia PS NP abutment.

# NobelReplace Platform Shift



Definitive restoration on NobelReplace PS implant.