

Clinical Case

NobelReplace Conical Connection

October, 2011



NobelReplace Conical Connection



Dr. Roberto Villa

Oral Surgeon

Spain



Flap with augmentation

Female patient

19 years old

Implant:

NobelReplace CC RP

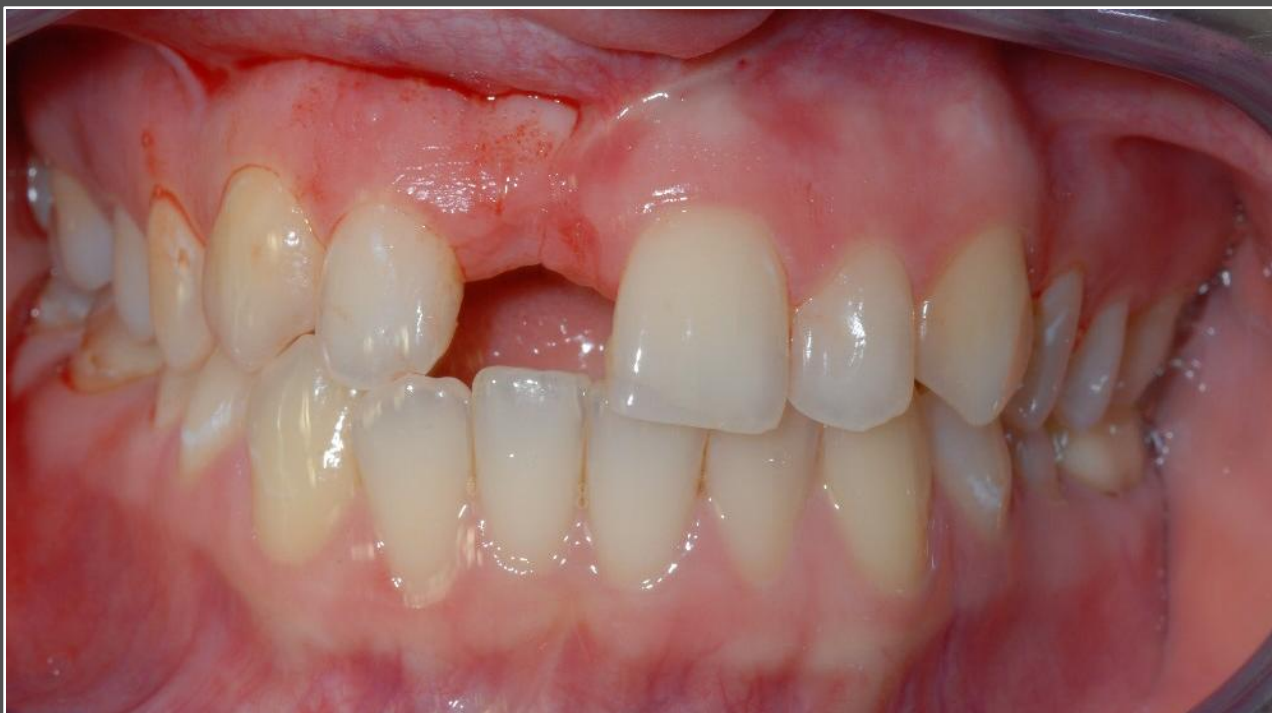4.3x13mm

Surgery date:

October 2nd, 2011

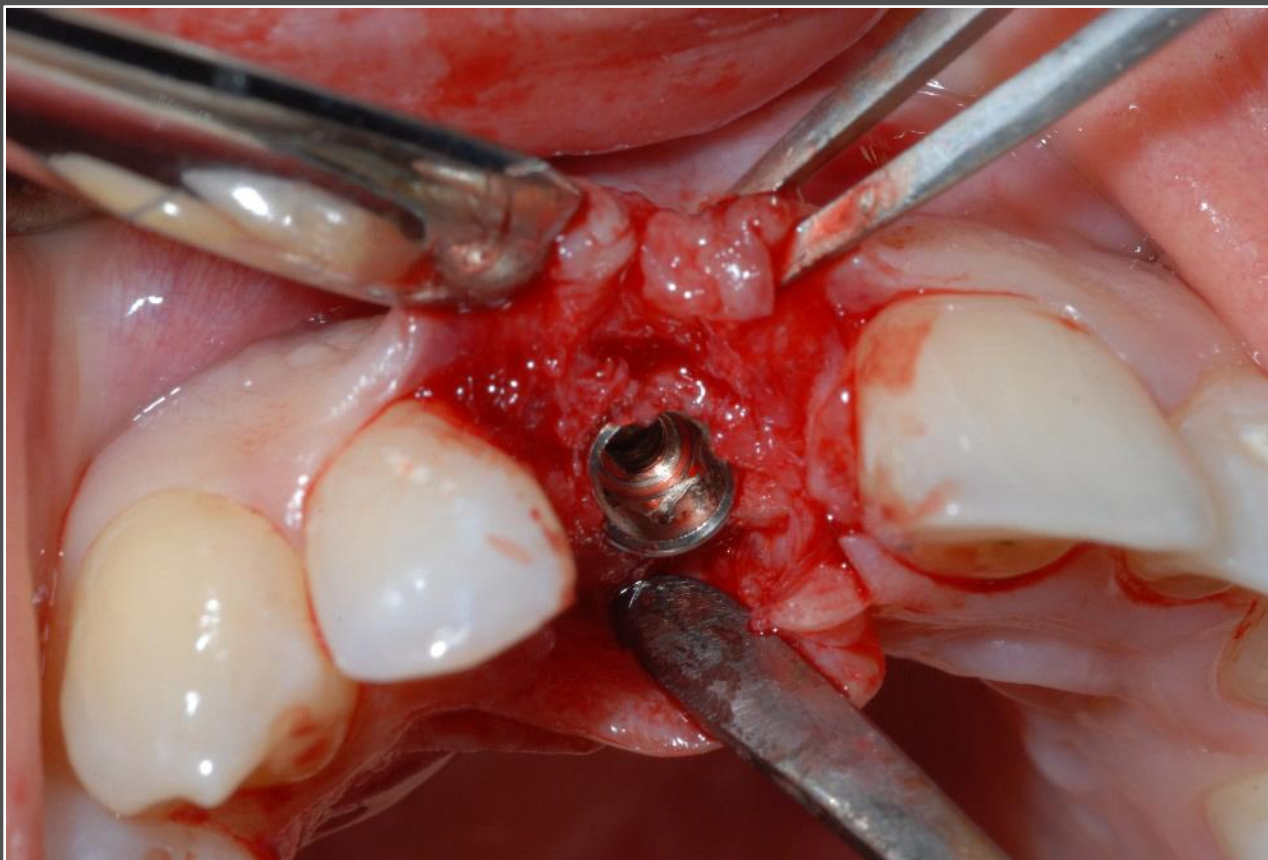FDI POS: tooth 11

NobelReplace Conical Connection



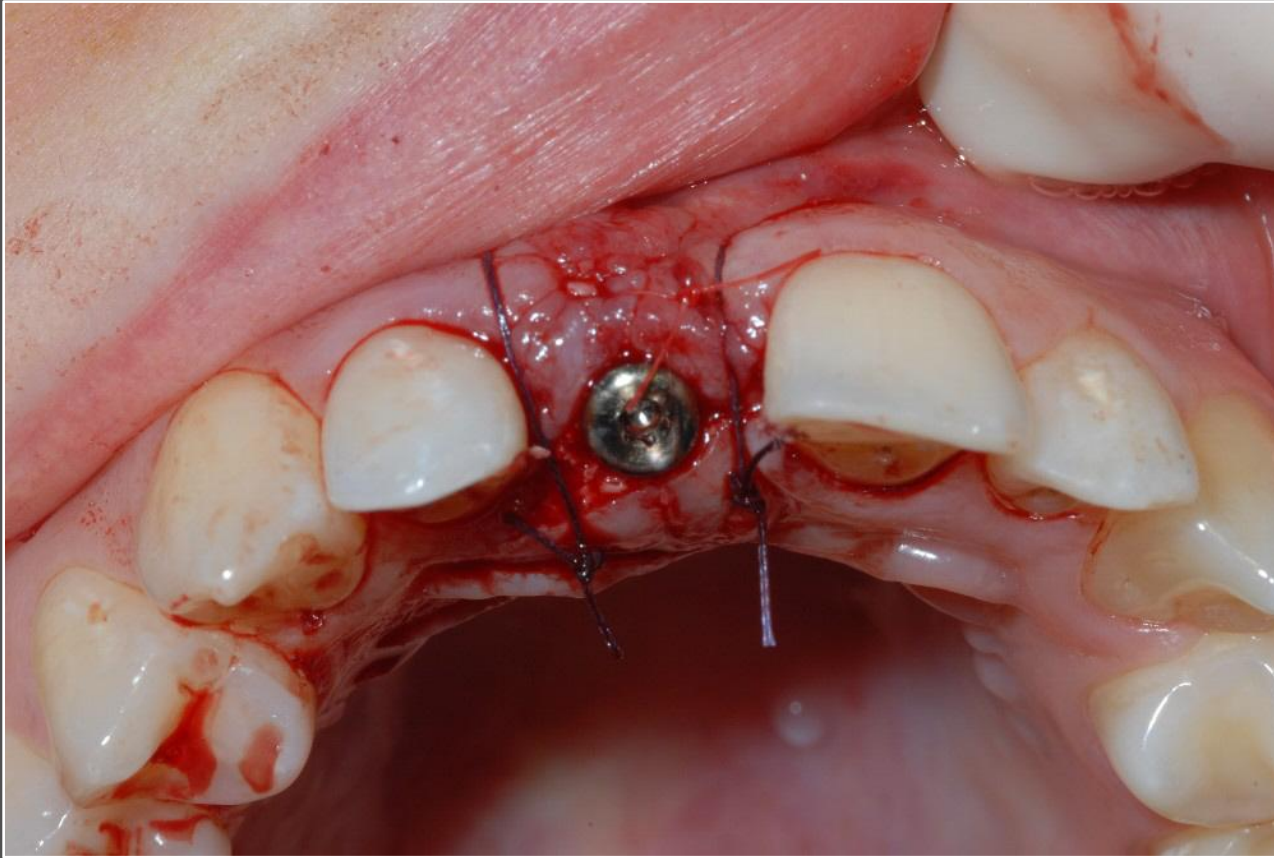
Initial clinical situation

NobelReplace Conical Connection



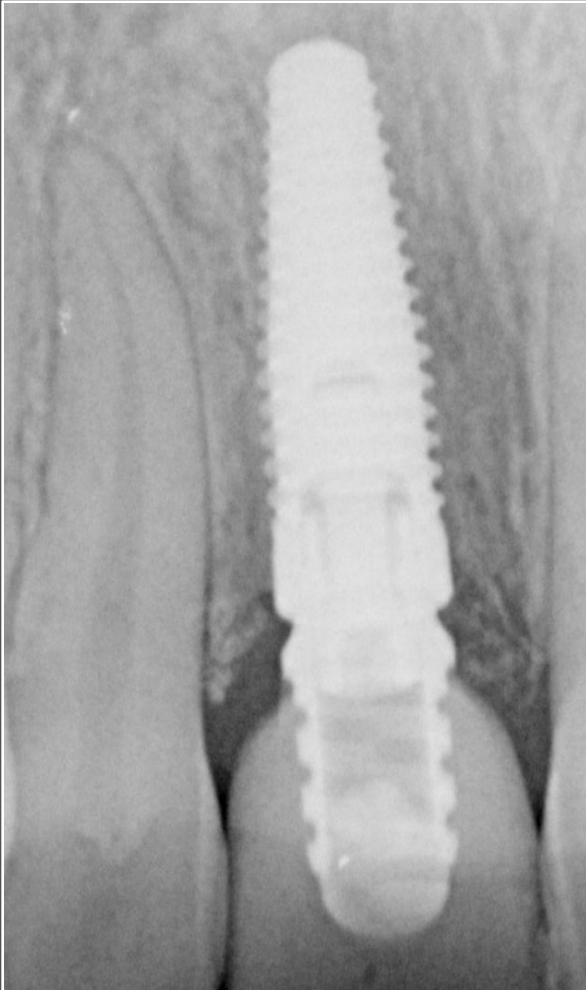Placement of NobelReplace CC implant.

NobelReplace Conical Connection



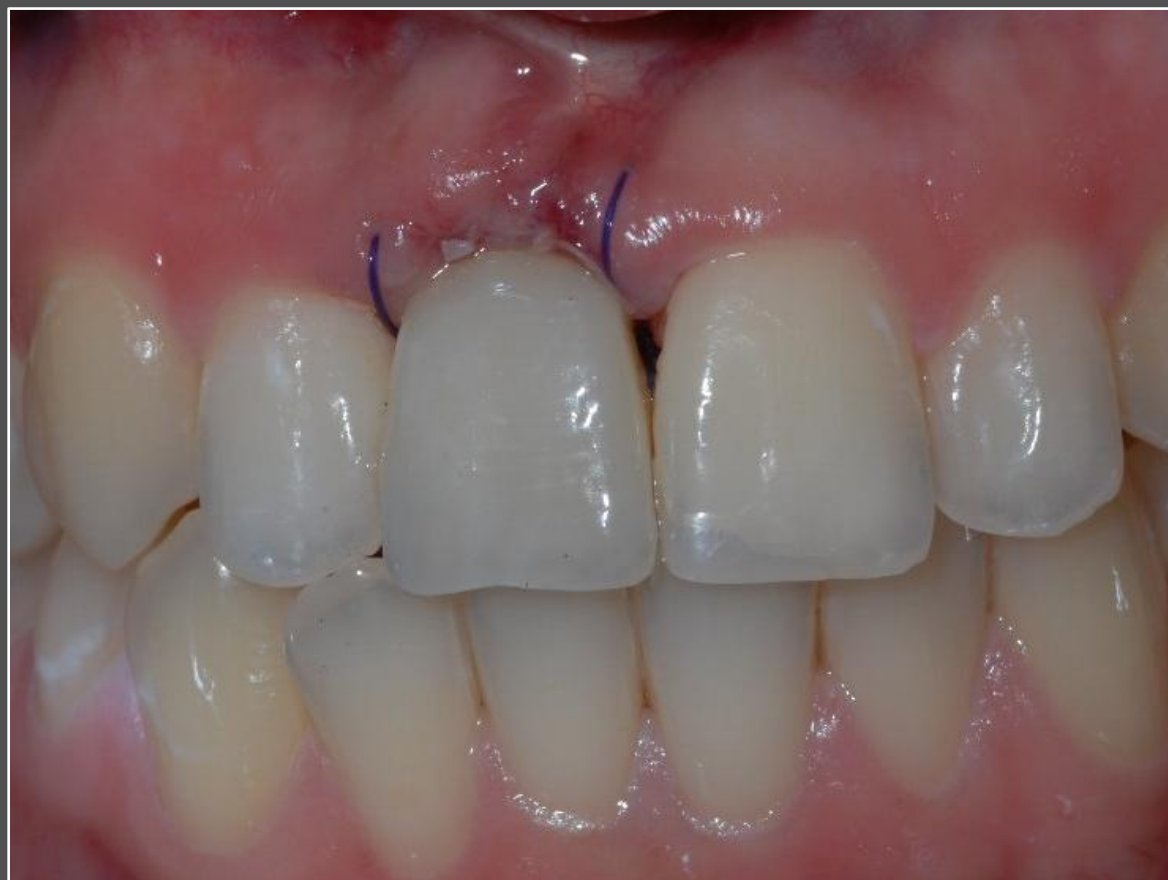Surgical sit with soft tissue graft and healing abutment in place.

NobelReplace Conical Connection



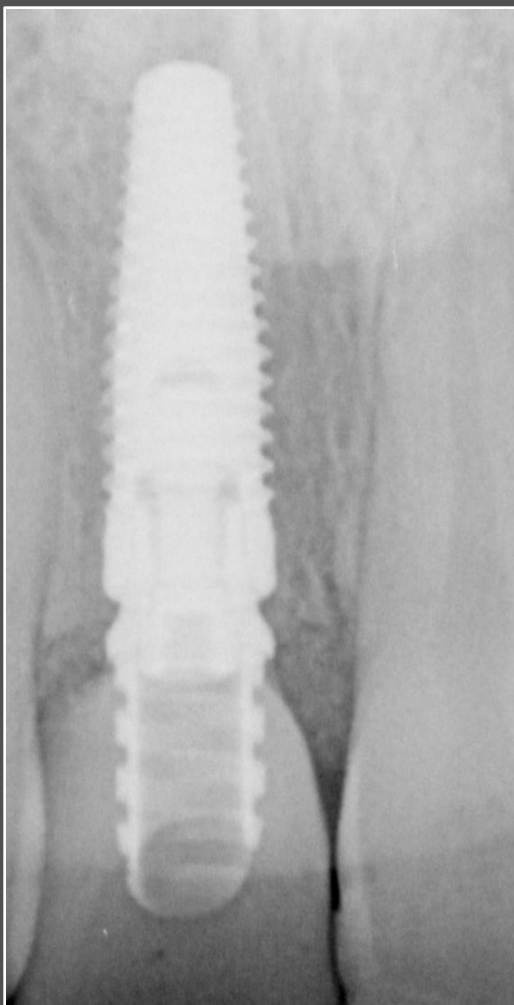
Radiograph following implant insertion and temporary restoration.

NobelReplace Conical Connection



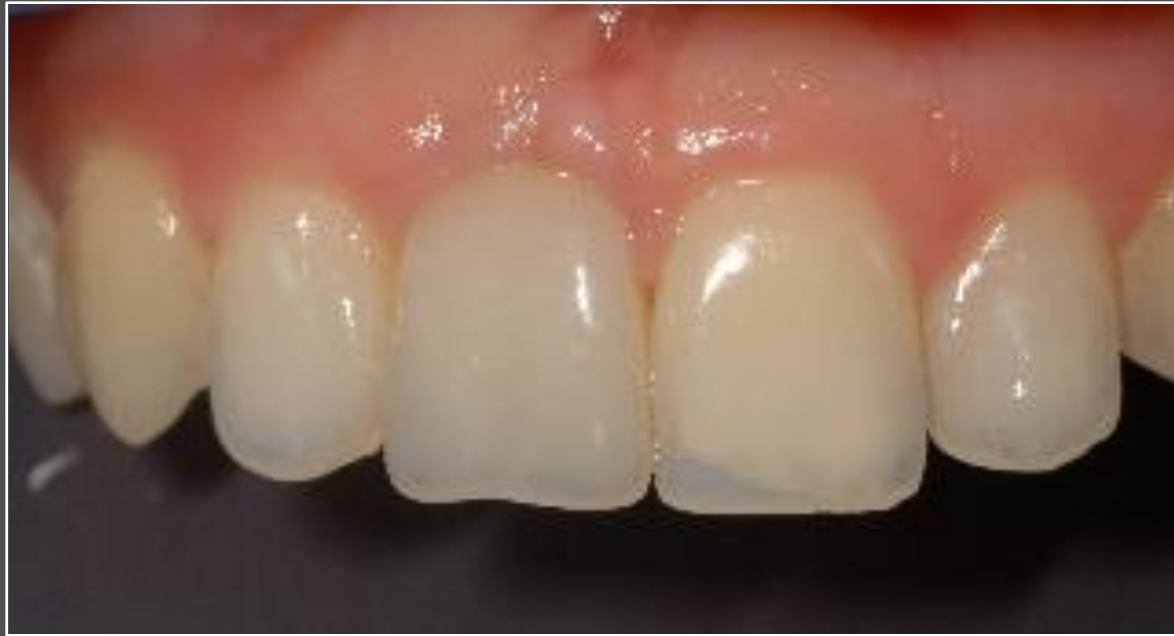Temporary restoration on implant #11.

NobelReplace Conical Connection



Radiograph of implant and temporary restoration 4 months post-op.

NobelReplace Conical Connection



Temporary restoration on implants after 4 months healing