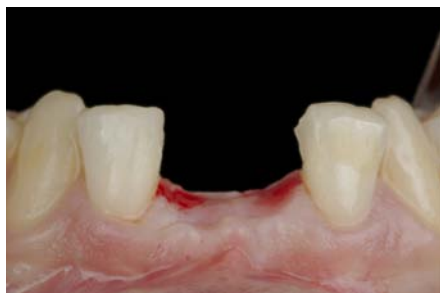

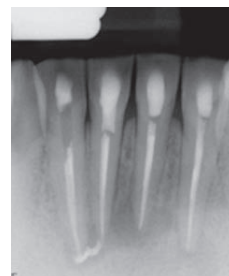
Narrow space restoration

22-year-old woman, good oral hygiene, non-smoker, no parafunctional habits

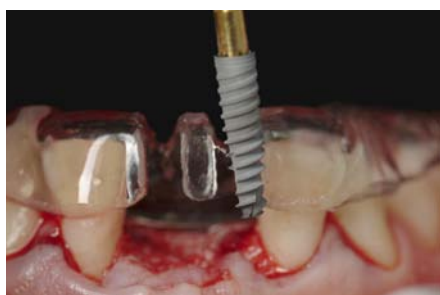


Diagnosis

Extraction of both lower central incisors needed due to extensive root infection and fractured teeth. Highly limited space conditions.

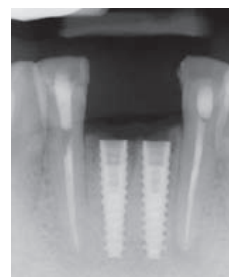


Pre-operative x-ray showing failed endodontic treatment

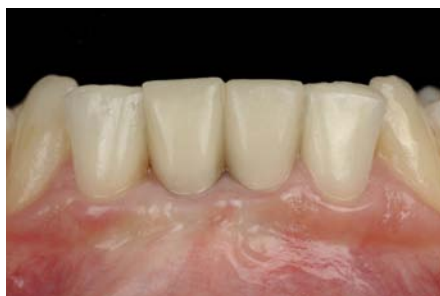

Implant placement

Placement of two NobelActive 3.0 x 13mm implants with immediate function protocol, including a connective tissue graft to increase soft tissue volume. A surgical guide was used to ensure optimal implant direction and depth.



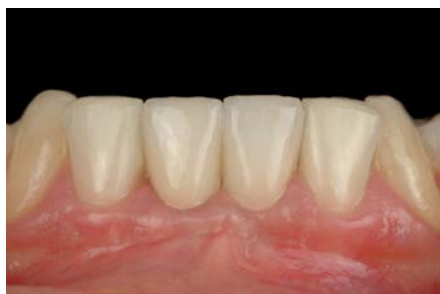NobelActive 3.0 implants in place



Provisional restoration

Development of an esthetic emergence profile three months after connective tissue graft maturation.

«The narrow profile of NobelActive 3.0 maintains the high initial stability and strength associated with the original NobelActive, making it an implant I trust for treating narrow space cases.»



Final restoration

Two NobelProcera Zirconia Crowns cemented on NobelProcera Abutments seven months after surgery.



Dr Iñaki Gamborena
San Sebastián, Spain